



Protocol for the Examination of Specimens From Patients With Carcinoma of the Penis

Version: 4.1.0.0

Protocol Posting Date: June 2021

CAP Laboratory Accreditation Program Protocol Required Use Date: March 2022

The changes included in this current protocol version affect accreditation requirements. The new deadline for implementing this protocol version is reflected in the above accreditation date.

For accreditation purposes, this protocol should be used for the following procedures AND tumor types:

Procedure	Description
Penectomy	Includes specimens designated partial penectomy and total penectomy.
Circumcision	Required if margins can be assessed.
Tumor Type	Description
Carcinoma	Includes carcinomas arising from foreskin glands or penile shaft.

This protocol is NOT required for accreditation purposes for the following:

Procedure
Biopsy (incisional or excisional)
Primary resection specimen with no residual cancer (eg, following neoadjuvant therapy)
Cytologic specimens

The following tumor types should NOT be reported using this protocol:

Tumor Type
Urothelial carcinoma (consider Urethra protocol)
Lymphoma (consider the Hodgkin or non-Hodgkin Lymphoma protocols)
Sarcoma (consider the Soft Tissue protocol)

Authors

Antonio L. Cubilla, MD*; Gladell P. Paner, MD*; Ming Zhou, MD, PhD*; Lara R. Harik, MD; Robert Allan, MD; Mahul B. Amin, MD; Jonathan I. Epstein, MD; David J. Grignon, MD; Peter A. Humphrey, MD, PhD; Curtis A. Pettaway, MD; Jason Pettus, MD; Victor E. Reuter, MD; John R. Srigley, MD; Elsa F. Velazquez, MD.

With guidance from the CAP Cancer and CAP Pathology Electronic Reporting Committees.

* Denotes primary author.

Accreditation Requirements

This protocol can be utilized for a variety of procedures and tumor types for clinical care purposes. For accreditation purposes, only the definitive primary cancer resection specimen is required to have the core and conditional data elements reported in a synoptic format.

- Core data elements are required in reports to adequately describe appropriate malignancies. For accreditation purposes, essential data elements must be reported in all instances, even if the response is “not applicable” or “cannot be determined.”
- Conditional data elements are only required to be reported if applicable as delineated in the protocol. For instance, the total number of lymph nodes examined must be reported, but only if nodes are present in the specimen.
- Optional data elements are identified with “+” and although not required for CAP accreditation purposes, may be considered for reporting as determined by local practice standards.

The use of this protocol is not required for recurrent tumors or for metastatic tumors that are resected at a different time than the primary tumor. Use of this protocol is also not required for pathology reviews performed at a second institution (ie, secondary consultation, second opinion, or review of outside case at second institution).

Synoptic Reporting

All core and conditionally required data elements outlined on the surgical case summary from this cancer protocol must be displayed in synoptic report format. Synoptic format is defined as:

- Data element: followed by its answer (response), outline format without the paired Data element: Response format is NOT considered synoptic.
- The data element should be represented in the report as it is listed in the case summary. The response for any data element may be modified from those listed in the case summary, including “Cannot be determined” if appropriate.
- Each diagnostic parameter pair (Data element: Response) is listed on a separate line or in a tabular format to achieve visual separation. The following exceptions are allowed to be listed on one line:
 - Anatomic site or specimen, laterality, and procedure
 - Pathologic Stage Classification (pTNM) elements
 - Negative margins, as long as all negative margins are specifically enumerated where applicable
- The synoptic portion of the report can appear in the diagnosis section of the pathology report, at the end of the report or in a separate section, but all Data element: Responses must be listed together in one location

Organizations and pathologists may choose to list the required elements in any order, use additional methods in order to enhance or achieve visual separation, or add optional items within the synoptic report. The report may have required elements in a summary format elsewhere in the report IN ADDITION TO but not as replacement for the synoptic report ie, all required elements must be in the synoptic portion of the report in the format defined above.

Summary of Changes

v 4.1.0.0

- General Reformatting
- Revised Margins Section
- Revised Lymph Nodes Section
- Added Distant Metastasis Section
- Removed pTX and pNX Staging Classification

Reporting Template

Protocol Posting Date: June 2021

Select a single response unless otherwise indicated.

CASE SUMMARY: (PENIS)

Standard(s): AJCC-UICC 8

This case summary is recommended for reporting biopsy specimens, but is not required for accreditation purposes.

SPECIMEN (Note [A](#))

Procedure

- Incisional biopsy
 Excisional biopsy
 Partial penectomy
 Total penectomy
 Circumcision
 Other (specify): _____
 Not specified

Foreskin (presence and type)

- Not identified (circumcised)
 Present (uncircumcised)
 Short
 Medium
 Long
 Phimotic
 Cannot be determined: _____

TUMOR

+Tumor Focality

- Unifocal
 Multifocal: _____

Tumor Site (select all that apply)

- Glans: _____
 Foreskin mucosal surface: _____
 Foreskin skin surface: _____
 Coronal sulcus (balanopreputial sulcus): _____
 Skin of the shaft: _____
 Shaft: _____
 Penile urethra: _____
 Penis, NOS: _____

+Tumor Macroscopic Features (select all that apply)

- Flat
 Ulcerated
 Polypoid
 Verruciform

- Necrosis
- Hemorrhage
- Other (specify): _____

Tumor Size

- Greatest dimension in Centimeters (cm): _____ cm
- +Additional Dimension in Centimeters (cm):** ____ x ____ cm
- Cannot be determined (explain): _____

Histologic Type (Note B)

Non-HPV-related squamous cell carcinoma

- Squamous cell carcinoma, usual type
- Pseudohyperplastic carcinoma
- Pseudoglandular carcinoma
- Verrucous carcinoma
- Carcinoma cuniculatum
- Papillary squamous cell carcinoma, NOS
- Adenosquamous carcinoma
- Sarcomatoid squamous cell carcinoma

HPV-related squamous cell carcinoma

- Basaloid squamous cell carcinoma
- Papillary-basaloid squamous cell carcinoma
- Warty carcinoma
- Warty-basaloid squamous cell carcinoma
- Clear cell squamous cell carcinoma
- Lymphoepithelioma-like carcinoma

Other Histologic Type

- Paget disease
- Adnexal carcinoma (specify type): _____
- Carcinoma, type cannot be determined: _____
- Other histologic type not listed (specify): _____

+Histologic Type Comment: _____

Histologic Grade (Note C)

- G1, well-differentiated
- G2, moderately differentiated
- G3, poorly differentiated
- Other (specify): _____
- GX, cannot be assessed: _____
- Not applicable: _____

+Tumor Thickness / Depth of Invasion (Note D)

- Specify in Millimeters (mm): _____ mm
- Other (specify): _____
- Cannot be determined: _____

+Tumor Deep Borders (Note E) (select all that apply)

- Pushing (broadly based)
- Infiltrative (jagged)
- Other (specify): _____

Tumor Extent (select all that apply)

- Carcinoma in situ
- Noninvasive localized squamous cell carcinoma
- Invades lamina propria
- Invades dermis
- Invades dartos fascia
- Invades corpus spongiosum
- Invades corpus cavernosum
- Invades tunica albuginea
- Invades Buck's fascia
- Invades penile (distal) urethra
- Invades regional skin (pubis, inguinal)
- Invades adjacent structure(s) (i.e., scrotum, prostate, pubic bone) (specify): _____
- Invades other structure(s) (specify): _____
- Cannot be determined (explain): _____
- No evidence of primary tumor

Lymphovascular Invasion (Note [F](#))

- Not identified
- Present
- Cannot be determined: _____

Perineural Invasion (Note [G](#))

- Not identified
- Present
- Cannot be determined: _____

+Tumor Comment: _____

MARGINS (Note [H](#))

Margin Status for Invasive Carcinoma

- All margins negative for invasive carcinoma

+Closest Margin(s) to Invasive Carcinoma (select all that apply)

- Urethral: _____
- Periurethral tissues (subepithelial connective tissue [lamina propria], corpus spongiosum, Buck's fascia) : _____
- Corpus cavernosum: _____
- Buck's fascia at penile shaft: _____
- Skin: _____
- # For circumcision specimens only*
- Coronal sulcus mucosal#: _____
- Cutaneous#: _____
- Other (specify): _____
- Cannot be determined (explain): _____

+Distance from Invasive Carcinoma to Closest Margin

Specify in Millimeters (mm)

- Exact distance: _____ mm
- Greater than: _____ mm

- At least: _____ mm
- Less than: _____ mm
- Less than 1 mm
- Other (specify): _____
- Cannot be determined: _____

Invasive carcinoma present at margin

Margin(s) Involved by Invasive Carcinoma (select all that apply)

- Urethral: _____
- Periurethral tissues (subepithelial connective tissue [lamina propria], corpus spongiosum, Buck's fascia) : _____
- Corpus cavernosum: _____
- Buck's fascia at penile shaft: _____
- Skin: _____
- # For circumcision specimens only*
- Coronal sulcus mucosal#: _____
- Cutaneous#: _____
- Other (specify): _____
- Cannot be determined (explain): _____

- Other (specify): _____
- Cannot be determined (explain): _____
- Not applicable

Margin Status for Noninvasive Carcinoma / Carcinoma in Situ

- All margins negative for non-invasive carcinoma / carcinoma in situ
- Noninvasive carcinoma / carcinoma in situ present at margin

Margin(s) Involved by Noninvasive Carcinoma / Carcinoma in Situ

- Specify involved margin(s): _____
- Cannot be determined (explain): _____
- Other (specify): _____
- Cannot be determined (explain): _____
- Not applicable

+Margin Comment: _____

REGIONAL LYMPH NODES (Note !)

Regional Lymph Node Status

- Not applicable (no regional lymph nodes submitted or found)
- Regional lymph nodes present
 - All regional lymph nodes negative for tumor
 - Tumor present in regional lymph node(s)

Number of Lymph Nodes with Tumor

- Exact number (specify): _____
- At least (specify): _____
- Other (specify): _____
- Cannot be determined (explain): _____

Nodal Site(s) with Tumor (select all that apply)

Sentinel: _____

Inguinal: _____

Number of Inguinal Lymph Nodes with Tumor

Exact number (specify): _____

At least (specify): _____

Other (specify): _____

Cannot be determined (explain): _____

Laterality of Inguinal Lymph Node(s) with Tumor

Unilateral

Bilateral

Cannot be determined (explain): _____

Pelvic: _____

Other (specify): _____

Cannot be determined

+Size of Largest Nodal Metastatic Deposit

Specify in Centimeters (cm)

Exact size: _____ cm

At least: _____ cm

Greater than: _____ cm

Less than: _____ cm

Other (specify): _____

Cannot be determined: _____

+Nodal Site with Largest Metastatic Deposit (specify site): _____

+Size of Largest Lymph Node with Tumor

Specify in Centimeters (cm)

Exact size: _____ cm

At least: _____ cm

Greater than: _____ cm

Less than: _____ cm

Other (specify): _____

Cannot be determined

+Largest Lymph Node with Tumor (specify site): _____

Extranodal Extension

Not identified

Present

Cannot be determined: _____

Other (specify): _____

Cannot be determined (explain): _____

Number of Lymph Nodes Examined

- Exact number (specify): _____
- At least (specify): _____
- Other (specify): _____
- Cannot be determined (explain): _____

+Regional Lymph Node Comment: _____

DISTANT METASTASIS**Distant Site(s) Involved, if applicable (select all that apply)**

- Not applicable
- Site(s) outside the true pelvis: _____
- Lung: _____
- Liver: _____
- Cutaneous nodules distant from the primary site: _____
- Bone: _____
- Other (specify): _____
- Cannot be determined: _____

PATHOLOGIC STAGE CLASSIFICATION (pTNM, AJCC 8th Edition) (Note J)

Reporting of pT, pN, and (when applicable) pM categories is based on information available to the pathologist at the time the report is issued. As per the AJCC (Chapter 1, 8th Ed.) it is the managing physician's responsibility to establish the final pathologic stage based upon all pertinent information, including but potentially not limited to this pathology report.

TNM Descriptors (select all that apply)

- Not applicable: _____
- m (multiple primary tumors)
- r (recurrent)
- y (post-treatment)

pT Category

- pT not assigned (cannot be determined based on available pathological information)
- pT0: No evidence of primary tumor
- pTis: Carcinoma *in situ* (Penile intraepithelial neoplasia [PeIN])
- pTa: Noninvasive localized squamous cell carcinoma
- pT1: (Glans) Tumor invades lamina propria; (Foreskin) Tumor invades dermis, lamina propria, or dartos fascia; (Shaft) Tumor invades connective tissue between epidermis and corpora regardless of location; All sites with or without lymphovascular invasion or perineural invasion and is or is not high grade*
- pT1a: Tumor is without lymphovascular invasion or perineural invasion and is not high grade (i.e., grade 3 or sarcomatoid)
- pT1b: Tumor exhibits lymphovascular invasion and / or perineural invasion or is high grade (i.e., grade 3 or sarcomatoid)
- pT1 (subcategory cannot be determined)
- pT2: Tumor invades into corpus spongiosum (either glans or ventral shaft) with or without urethral invasion
- pT3: Tumor invades into corpora cavernosum (including tunica albuginea) with or without urethral invasion
- pT4: Tumor invades into adjacent structures (i.e., scrotum, prostate, pubic bone)

pN Category

- pN not assigned (no nodes submitted or found)
- pN not assigned (cannot be determined based on available pathological information)
- pN0: No lymph node metastasis
- pN1: less than or equal to 2 unilateral inguinal metastases, no extranodal extension
- pN2: greater than or equal to 3 unilateral inguinal metastases or bilateral metastases, no ENE
- pN3: Extranodal extension of lymph node metastases or pelvic lymph node metastases

pM Category (required only if confirmed pathologically)

- Not applicable - pM cannot be determined from the submitted specimen(s)
- * Including lymph node metastasis outside the true pelvis, lung, liver, cutaneous nodules distant from the primary site, and bone.*
- pM1: Distant metastasis present[#]

ADDITIONAL FINDINGS (Note [K](#))

+Additional Findings (select all that apply)

- None identified
- HPV-related penile intraepithelial neoplasia (PeIN), warty type
- HPV-related penile intraepithelial neoplasia (PeIN), basaloid type
- HPV-related penile intraepithelial neoplasia (PeIN), warty-basaloid type
- Non-HPV-related PeIN (differentiated [simplex] penile intraepithelial neoplasia)
- Pleomorphic PeIN
- Spindle PeIN
- Clear cell PeIN
- Pagetoid PeIN
- Lichen sclerosus
- Squamous hyperplasia
- Condyloma acuminatum
- Other (specify): _____

SPECIAL STUDIES

+Ancillary Studies

- Specify: _____
- Not performed

COMMENTS

Comment(s): _____

Explanatory Notes

A. Types of Foreskin

There are three foreskin types: in the short foreskin, the preputial orifice is located behind the glans corona; in the medium foreskin, the orifice is between the corona and the meatal orifice; in the long foreskin, the entire glans is covered and the meatus is not identified without retracting the foreskin. Phimotic foreskins are unretractable and long.¹ Phimosis is present in up to one-half of patients with penile carcinoma,¹ and its presence is considered a risk factor for the development of this tumor.^{2,3,4}

References

1. Velazquez EF, Bock A, Soskin A, Codas R, Arbo M, Cubilla AL. Preputial variability and preferential association of long phimotic foreskins with penile cancer: an anatomic comparative study of types of foreskin in a general population and cancer patients. *Am J Surg Pathol*. 2003;27(7):994-998.
2. Daling J, Madeleine MM, Johnson LG, et al. Penile cancer: importance of circumcision, human papillomavirus and smoking in situ and invasive disease. *Int J Cancer*. 2005;116(4):606-616.
3. Tsen HF, Morgenstern H, Mack T, Peters RK. Risk factors for penile cancer: results of a population-based case-control study in Los Angeles County (United States). *Cancer Causes Control*. 2002;12(3):267-277.
4. Madsen BS, van den Brule AJ, Jensen HL, Wholfahrt J, Frisch M. Risk factors for squamous cell carcinoma of the penis: population-based case-control study in Denmark. *Cancer Epidemiol Biomarkers Prev*. 2008;17(10):2683-2691.

B. Histologic Subtype of Squamous Cell Carcinoma

The World Health Organization (WHO) classification of tumors of the penis was recently published.¹ Most penile cancers are squamous cell carcinomas (SCC), and most arise from the epithelium of the distal portion of the penis (including glans, coronal sulcus, and mucosal surface of the prepuce). Squamous cell carcinoma of the usual type (keratinizing SCC) comprises about 50% to 60% of all cases.^{2,3,4} There are other SCC variants showing distinctive morphological and outcome features.^{3,4,5} The different histological subtypes correlate with different rates of regional/nodal and systemic dissemination. Penile cancer subtypes can be prognostically stratified in three groups. The low-risk group includes verruciform tumors such as verrucous, papillary, and warty/condylomatous carcinomas.^{5,6} More recently described subtypes, such as pseudohyperplastic and carcinoma cuniculatum of the penis, also belong to this category of excellent prognosis.^{7,8} The high-risk category is comprised by basaloid, sarcomatoid, adenosquamous, and poorly differentiated SCC of the usual type.^{9,10,11} There is an intermediate category of metastatic risk that includes most SCCs of the usual type, some mixed neoplasms (such as hybrid verrucous carcinomas), and high-grade variants of warty/condylomatous carcinomas.⁶

References

1. Moch H, Humphrey PA, Ulbright TM, Reuter VE. WHO Classification of Tumours of the Urinary System and Male Genital Organs. Geneva, Switzerland: WHO Press; 2016.
2. Epstein JH, Humphrey PA, Cubilla AL. Tumors of the Prostate Gland, Seminal Vesicles, Male Urethra, Penis and Scrotum. Washington, DC: Armed Forces Institute of Pathology; 2011 Atlas of Tumor Pathology.
3. Cubilla AL, Dillner J, Schellhammer PF, Horenblas S. Malignant epithelial tumors. In: Eble JN, Sauter G, Epstein J, Sesterhenn I, eds. *Pathology and Genetics of Tumors of the Urinary System and Male Genital Organs*. Lyon, France: IARC Press; 2004. World Health Organization Classification of Tumours.
4. Velazquez EF, Barreto JE, Ayala G, Cubilla AL. Penis. In: Mills SE, Carter D, Greenson JK, et al, eds. *Sternberg's Diagnostic Surgical Pathology*. 5th ed. Philadelphia, PA: Lippincott Williams & Wilkins; 2009.

5. Cubilla AL, Reuter V, Velazquez E, Piris A, Saito S, Young RH. Histologic classification of penile carcinoma and its relation to outcome in 61 patients with primary resection. *Int J Surg Pathol.* 2001;9(2):111-120.
6. Cubilla AL, Velazques EF, Reuter VE, Oliva E, Mihm MC Jr, Young RH. Warty (condylomatous) squamous cell carcinoma of the penis: a report of 11 cases and proposed classification of verruciform tumors penile tumors. *Am J Surg Pathol.* 2000;24(4):505-512.
7. Cubilla AL, Velazquez EF, Young RH. Pseudohyperplastic squamous cell carcinoma of the penis associated with lichen sclerosus — an extremely well-differentiated nonverruciform neoplasm that preferentially affects the foreskin and is frequently misdiagnosed: a report of 10 cases of a distinctive clinicopathologic entity. *Am J Surg Pathol.* 2004;28(7):895-900.
8. Barreto JE, Velazquez EF, Ayala E, Torres J, Cubilla AL. Carcinoma cuniculatum of the penis — a distinctive variant of penile squamous cell carcinoma: report of 7 cases. *Am J Surg Pathol.* 2007;31(1):71-75.
9. Cubilla AL, Reuter VE, Gregoire L, et al. Basaloid squamous cell carcinoma: a distinctive HPV related penile neoplasm: a report of 20 cases. *Am J Surg Pathol.* 1998;22(6):751-761.
10. Velazquez EF, Melamed J, Barreto JE, Aguero F, Cubilla AL. Sarcomatoid carcinoma of the penis: a clinico-pathological study of 14 cases. *Am J Surg Pathol.* 2005;29(9):1152-1158.
11. Cubilla AL, Ayala MT, Barreto JE, Bellasai JG, Noël JC. Surface adenosquamous carcinoma of the penis: a report of three cases. *Am J Surg Pathol.* 1996;20(2):156-160.

C. Histologic Grade

Histological grade has been consistently reported as an influential predictive factor of groin metastasis and dissemination of penile cancer.^{1,2,3} We recommend a method to grade penile SCCs as follows:

- Grade 1 is an extremely well-differentiated carcinoma, with a minimal deviation from the morphology of normal/hyperplastic squamous epithelium.
- Grade 2 tumors show a more disorganized growth as compared to grade 1 lesions, higher nuclear-to-cytoplasmic ratio, evident mitoses, and, although present, less prominent keratinization.
- Grade 3 are tumors showing any proportion of anaplastic cells, identified as solid sheets or irregular small aggregates, cords or nests of cells with little or no keratinization, high nuclear-to-cytoplasmic ratio, thick nuclear membranes, nuclear pleomorphism, clumped chromatin, prominent nucleoli, and numerous mitosis.^{3,4}

A tumor should be graded according to the least differentiated component. Any proportion of grade 3 should be noted in the report.⁴

References

1. Slaton JW, Morgenstern N, Levy DA, et al. Tumor stage, vascular invasion and the percentage of poorly differentiated cancer: independent prognosticators for inguinal node metastasis in penile squamous cancer. *J Urol.* 2001;165(4):1138-1142.
2. Cubilla AL, Velazquez EF, Ayala GE, Chaux A, Torres J, Reuter V. Identification of prognostic pathologic parameters in squamous cell carcinoma of the penis: significance and difficulties. *Pathol Case Rev.* 2005;10:3-13.
3. Velazquez EF, Ayala G, Liu H, et al. Histologic grade and perineural invasion are more important than tumor thickness as predictor of nodal metastasis in penile squamous cell carcinoma invading 5 to 10 mm. *Am J Surg Pathol.* 2008;32(7):974-979.
4. Chaux A, Torres J, Pfannl R, et al. Histologic grade in penile squamous cell carcinoma: visual estimation versus digital measurement of proportions of grades, adverse prognosis with any proportion of grade 3 and correlation of a Gleason-like system with nodal metastasis. *Am J Surg Pathol.* 2009;33:1042-1048.

D. Depth of Invasion

The tumor depth in small lesions is best obtained by perpendicularly sectioning along the tumor central axis. For large glans tumors, it is preferred to section the specimen longitudinally in half, with additional parallel sections of each half, using as an axis the central and ventral penile urethra. The depth of invasion of SCC is defined as a measurement in millimeters from the epithelial-stromal junction of the adjacent nonneoplastic epithelium to the deepest point of invasion. In larger tumors, especially verruciform ones, the previously mentioned system is not applicable, and we measure the thickness from the surface (excluding the keratin layer) to the deepest point of invasion. Depth of invasion and tumor thickness are of equivalent significance. There is a correlation between depth of invasion and outcome in penile cancers. Minimal risk for metastasis was reported for tumors measuring less than 5 mm in thickness.^{1,2} Tumors invading deeper into penile anatomical levels are usually associated with a higher risk for nodal involvement. There is also a correlation between deeper infiltration and higher histological grade, although some exceptions do occur.³ Tumors invading corpus cavernosum are at higher risk for presenting nodal metastases than those invading only corpus spongiosum,^{3,4} and the deepest erectile tissue invaded should be clearly stated in the final pathology report. Per AJCC 8th edition, tumor invading into subepithelial connective tissue (lamina propria), Dartos muscle, and Buck's fascia is staged as T1; tumor invading into corpus spongiosum (either glans or ventral shaft) with or without urethral invasion is staged as T2; tumor invading into corpora cavernosum (including tunica albuginea) with or without urethral invasion is staged as T3; and tumor invading into adjacent structures (ie, scrotum, prostate, pubic bone) is staged as T4.

References

1. Velazquez EF, Ayala G, Liu H, et al. Histologic grade and perineural invasion are more important than tumor thickness as predictor of nodal metastasis in penile squamous cell carcinoma invading 5 to 10 mm. *Am J Surg Pathol.* 2008;32(7):974-979.
1. Emerson RE, Ulbright TM, Eble JN, Geary WA, Eckert GJ, Cheng L. Predicting cancer progression in patients with penile squamous cell carcinoma: the importance of depth of invasion and vascular invasion. *Mod Pathol.* 2001;14(10):963-968.
2. Leijte J, Gallee M, Antonini N, Horenblas S. Evaluation of current TNM classification of penile carcinoma. *J Urol.* 2008;180(3):933-938.
3. Chaux A, Caballero C, Soares F, et al. The prognostic index: a useful pathologic guide for prediction of nodal metastases and survival in penile squamous cell carcinoma. *Am J Surg Pathol.* 2009;33(7):1049-1057.

E. Tumor Base of Infiltration

Two patterns are recognized: infiltrating (invasion in blocks of small solid strands of cell tumors broadly infiltrating the stroma) and pushing infiltration (tumor cells invading in large cell blocks with well-defined tumor-stroma interface). The infiltrating pattern of invasion is associated with a higher risk for nodal involvement.¹

References

1. Guimarães G, Lopes A, Campos RS, et al. Front pattern of invasion in squamous cell carcinoma of the penis: new prognostic factor for predicting risk of lymph node metastases. *Urology.* 2006;68(1):148-153.

F. Lymphovascular Invasion

Vascular invasion, lymphatic or venous, adversely affects prognosis of penile cancer.^{1,2,3,4,5} The TNM staging classification in the 8th edition of the AJCC Cancer Staging Manual subdivides T1 tumors into T1a and T1b based on the absence or presence of lymphovascular invasion or poorly differentiated tumors.⁶ Embolic involvement of lymphatic vascular spaces occurs usually near the invasive tumor front, but it may also be found at a certain distance from the primary tumor in anatomical areas such as the

lamina propria, penile fascia, and especially in the subepithelial connective tissues surrounding penile urethra. Venous invasion indicates a more advanced stage of the disease and is related to the compromise of the specialized erectile venous structures of corpora spongiosa and cavernosa.

References

1. Lopes A, Hidalgo GS, Kowalski LP, Torloni H, Rossi BM, Fonseca FP. Prognostic factors in carcinoma of the penis: multivariate analysis of 145 patients treated with amputation and lymphadenectomy. *J Urol.* 1996;156(5):1637-1642.
2. Ficarra V, Zattoni F, Cunico SC, et al. Lymphatic and vascular embolizations are independent predictive variables of inguinal node involvement in patients with squamous cell carcinoma of the penis: Gruppo Uro-Oncologico del Nord Est (Northeast Uro-Oncological Group) Penile Cancer data base data. *Cancer.* 2005;103(12):2507-2516.
3. Ficarra V, Zattoni F, Artibani W, et al; GUONE Penile Cancer Project Members. Nomogram predictive of pathological inguinal lymph node involvement in patients with squamous cell carcinoma of the penis. *J Urol.* 2006;175(6):1700-1705.
4. Kattan MW, Ficarra V, Artibani W, et al; GUONE Penile Cancer Project Members. Nomogram predictive of cancer specific survival in patients undergoing partial or total amputation for squamous cell carcinoma of the penis. *J Urol.* 2006;175(6):2103-2108.
5. Novara G, Galfano A, De Marco V, Artibani W, Ficarra V. Prognostic factors in squamous cell carcinoma of the penis. *Nat Clin Pract Urol.* 2007;4(3):140-146.
6. Amin MB, Edge SB, Greene FL, et al, eds. *AJCC Cancer Staging Manual.* 8th ed. New York, NY: Springer; 2017.

G. Nomograms, Risk Groups, and Perineural Invasion

An evaluation of clinical and pathological variables using a nomogram was recently developed.¹ The selected factors were clinical stage of lymph nodes, microscopic growth pattern, grade, vascular invasion, and invasion of corpora spongiosa and cavernosa and urethra. The probability of nodal metastasis as predicted by the nomogram was close to the real incidence of metastasis observed at follow up. A second nomogram to estimate predictions of survival at 5 years with the same clinical and pathological factors gave similar results.² More recently, perineural invasion and histological grade were found to be the strongest independent predictors of mortality in penile tumors 5 to 10 mm thick. A nomogram considering the predictive value of perineural invasion and histological grade was accordingly constructed.³ Risk groups stratification systems are available to predict the likelihood of inguinal nodal involvement and for therapeutic planning and are based on a combination of histological grade and pT stage.^{4,5,6,7} Strongest predictive power results from the combination of histological grade, deepest anatomical level of infiltration, and presence of perineural invasion. These factors are used for constructing the prognostic index.⁸

References

1. Ficarra V, Zattoni F, Artibani W, et al; GUONE Penile Cancer Project Members. Nomogram predictive of pathological inguinal lymph node involvement in patients with squamous cell carcinoma of the penis. *J Urol.* 2006;175(6):1700-1705.
2. Kattan MW, Ficarra V, Artibani W, et al; GUONE Penile Cancer Project Members. Nomogram predictive of cancer specific survival in patients undergoing partial or total amputation for squamous cell carcinoma of the penis. *J Urol.* 2006;175(6):2103-2108.
3. Cubilla AL, Velazquez EF, Ayala GE, Chaux A, Torres J, Reuter V. Identification of prognostic pathologic parameters in squamous cell carcinoma of the penis: significance and difficulties. *Pathol Case Rev.* 2005;10:3-13.
4. Solsona E, Iborra I, Rubio J, Casanova JL, Ricos JV, Calabuig C. Prospective validation of the association of local tumor stage and grade as a predictive factor for occult lymph node micrometastasis in patients with penile carcinoma and clinically negative inguinal lymph nodes. *J Urol.* 2001;165(5):1506-1509.

5. Solsona E, Algaba F, Horenblas S, Pizzocaro G, Windahl T; European Association of Urology. EAU guidelines on penile cancer. *Eur Urol.* 2004;46(1):1-8.
6. Hungerhuber E, Schlenker B, et al. Risk stratification in penile carcinoma: 25-year experience with surgical inguinal lymph node staging. *Urology.* 2006;68(3):621-625.
7. Ornellas AA, Nóbrega BL, Wei Kin Chin E, et al. Prognostic factors in invasive squamous cell carcinoma of the penis: analysis of 196 patients treated at the Brazilian National Cancer Institute. *J Urol.* 2008;180(4):1354-1359.
8. Chaux A, Caballero C, Soares F, et al. The prognostic index: a useful pathologic guide for prediction of nodal metastases and survival in penile squamous cell carcinoma. *Am J Surg Pathol.* 2009;33(7):1049-1057.

H. Resection Margins

Positive margins adversely affect prognosis in patients with penile squamous cell carcinomas.^{1,2,3} Important margins to be examined in partial penectomy specimens include: (1) proximal urethra and surrounding periurethral cylinder consisting of epithelium, subepithelial connective tissue (lamina propria), corpus spongiosum, and penile fascia; (2) proximal shaft with corresponding corpora cavernosa separated and surrounded by the tunica albuginea and Buck's fascia; and (3) skin of shaft with underlying corporal dartos⁴ (Figure 1). The coronal sulcus mucosal margin and cutaneous margin should be entirely examined when evaluating circumcision specimens.

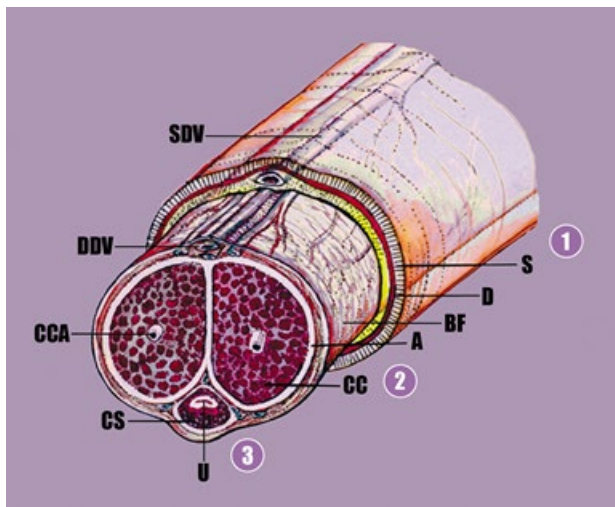


Figure 1. Partial penectomy specimen; anatomical structures of proximal resection margin. The ventral urethra (U) is surrounded by the corpus spongiosum (CS) and a delicate white tunica albuginea (A). The latter is also surrounding the corpora cavernosa (CC). The penile fascia (Buck's fascia) (BF) is located underneath skin (S) and dartos (D). The proximal margin of resection should be cut en face and all the structures including the entire circumference of the urethra with periurethral cylinder should be examined. The 3 important margins to be examined include (1) skin of the shaft with underlying dartos and penile fascia, (2) the corpora cavernosa with surrounding tunica albuginea, and (3) the urethra and periurethral cylinder that includes the lamina propria, corpus spongiosum, albuginea, and penile fascia.

Abbreviations: CCA, cavernous artery; DDV, deep dorsal vein; SDV, superficial dorsal vein.

References

1. Epstein JH, Humphrey PA, Cubilla AL. *Tumors of the Prostate Gland, Seminal Vesicles, Male Urethra, Penis and Scrotum.* Washington, DC: Armed Forces Institute of Pathology; 2011 Atlas of Tumor Pathology.

2. Velazquez EF, Barreto JE, Ayala G, Cubilla AL. Penis. In: Mills SE, Carter D, Greenson JK, et al, eds. Sternberg's Diagnostic Surgical Pathology. 5th ed. Philadelphia, PA: Lippincot Williams & Wilkins; 2009.
3. Velazquez EF, Soskin A, Bock A, Cudas R, Barreto JE, Cubilla AL. Positive resection margins in partial penectomies: sites of involvement and proposal of local routes of spread of penile squamous cell carcinoma. Am J Surg Pathol. 2004;28(3):384-389.
4. Chaux A, Caballero C, Soares F, et al. The prognostic index: a useful pathologic guide for prediction of nodal metastases and survival in penile squamous cell carcinoma. Am J Surg Pathol. 2009;33(7):1049-1057.

I. Number of Involved Lymph Nodes and Extension of the Lymphadenectomy

The presence of more than two positive lymph nodes in one inguinal basin increases the likelihood of contralateral inguinal and ipsilateral pelvic nodal involvement.¹ In such cases, prophylactic contralateral inguinal and ipsilateral pelvic lymphadenectomy is advised. The number and percentage of positive nodes involved also has an impact on survival.^{2,3}

References

1. Lont AP, Kroon BK, Gallee MP, van Tinteren H, Moonen LM, Horenblas S. Pelvic lymph node dissection for penile carcinoma: extent of inguinal lymph node involvement as an indicator for pelvic lymph node involvement and survival. J Urol. 2007;177(3):947-952.
2. Svatek RS, Munsell M, Kincaid JM, et al. Association between lymph node density and disease specific survival in patients with penile cancer. J Urol. In press.
3. Pandey D, Mahajan V, Kannan RR. Prognostic factors in node-positive carcinoma of the penis. J Surg Oncol. 2006;93(2):133-138.

J. TNM Staging Classification

The protocol recommends the use of the TNM staging system of the American Joint Committee on Cancer (AJCC) for carcinoma of the penis.¹ By AJCC convention, the designation T refers to a primary tumor that has not been previously treated. The symbol p refers to the pathologic classification of the TNM, as opposed to the clinical classification, and is based on gross and microscopic examination. pT entails a resection of the primary tumor or a biopsy adequate to evaluate the highest pT category, pN entails removal of nodes adequate to validate lymph node metastasis, and pM implies microscopic examination of distant lesion. Pathologic staging is usually performed after surgical resection of the primary tumor. The summary of changes in the TNM staging classification in the 8th edition of the AJCC Cancer Staging Manual is as follows:

Change	Details of Change
Histologic Grade (G)	The 3-tiered World Health Organization (WHO)/International Society of Urological Pathology (ISUP) grading system has been adopted. Any proportion of anaplastic cells is sufficient to categorize a tumor as grade 3.
Definition of Primary Tumor (T)	Ta definition is now broadened to include noninvasive localized squamous carcinoma.
Definition of Primary Tumor (T)	T1a and T1b have been separated by an additional prognostic indicator—the presence or absence of perineural invasion.
Definition of Primary Tumor (T)	T1a or T1b are described by the site where they occur on the penis and are designated glans, foreskin, or shaft. Anatomic layers invaded are described for the three locations.
Definition of Primary Tumor (T)	T2 definition includes corpus spongiosum invasion.
Definition of Primary Tumor (T)	T3 definition now involves corpora cavernosum invasion.

Change	Details of Change
Definition of Regional Lymph Nodes (N)	pN1 is defined as ≤ 2 unilateral inguinal metastases, no extranodal extension.
Definition of Regional Lymph Nodes (N)	pN2 is defined as ≥ 3 unilateral inguinal metastases or bilateral metastases

Additional Descriptor

The m suffix indicates the presence of multiple primary tumors and is recorded in parentheses, eg, pTa(m)NOM0.

Anatomic Stage/Prognostic Groups

Group	T	N	M
Stage 0is	Tis	N0	M0
Stage 0a	Ta	N0	M0
Stage I	T1a	N0	M0
Stage IIA	T1b	N0	M0
Stage IIA	T2	N0	M0
Stage IIB	T3	N0	M0
Stage IIIA	T1-3	N1	M0
Stage IIIB	T1-3	N2	M0
Stage IV	T4	Any N	M0
Stage IV	Any T	N3	M0
Stage IV	Any T	Any N	M1

Prognostic Factors (Site-Specific Factors)

Factors required for staging: None.

Clinically significant factors:

- Involvement of corpus spongiosum
- Involvement of corpus cavernosum
- Percentage of tumor that is poorly differentiated
- Verrucous carcinoma depth of invasion
- Size of largest lymph node metastasis
- Extranodal/extracapsular extension
- Human papillomavirus (HPV) status

References

1. Amin MB, Edge SB, Greene FL, et al, eds. AJCC Cancer Staging Manual. 8th ed. New York, NY: Springer; 2017.

K. Penile Intraepithelial Neoplasia

Penile Intraepithelial Neoplasia (PeIN) may be subclassified as differentiated (simplex), warty, basaloid, and warty/basaloid (mixed).^{1,2} Differentiated PeIN shows parakeratosis, epithelial thickening, elongation of rete ridges, prominent bridges, basal cell atypia, enlarged nuclei, and prominent nucleoli. Differentiated PeIN is frequently associated with lichen sclerosus. It is considered HPV-unrelated, there is no koilocytosis, and p16 immunohistochemical staining results (surrogate of high-risk types of HPV) are usually negative. Basaloid PeIN is characterized by a replacement of the normal epithelium by small, uniform cells with round nuclei and scant cytoplasm. Numerous mitosis and apoptotic cells are usually present. Warty PeIN shows a spiky surface with parakeratosis. The normal epithelium is replaced by

markedly pleomorphic cells showing prominent koilocytosis. Mixed warty-basaloid lesions are not infrequent. Warty and basaloid PeIN are HPV-related lesions and usually overexpress p16.

References

1. Cubilla AL, Pfannl R, Rodriguez I, et al. Morphological characterization and distribution of penile precancerous lesions using a simplified nomenclature: a study of 198 lesions in 115 patients. *Lab Invest.* 2008;88:696(A).
2. Pfannl R, Hernandez M, Velazquez EF, et al. Expression of p53 and p16 in differentiated and warty/basaloid penile intraepithelial neoplasia (PeIN). *Lab Invest.* 2008;88:807(A).

L. Handling of the Specimen

Circumcision Specimen

Take measurements, describe specimen, and identify and describe tumor. Identify and ink the mucosal and cutaneous margins with different colors. Most SCCs arise from the mucosal surface of the foreskin, therefore the coronal sulcus (mucosal) margin is especially important. Lightly stretch and pin the specimen to a cardboard. Fix for several hours in formalin. Cut vertically the whole specimen labeling from 1 to 12, clockwise.

Penectomy Specimen

Take measurements, describe specimen, and identify and describe tumor. Most SCCs of the penis arise from the epithelium of the distal portion of the organ (glans, coronal sulcus, and mucosal surface of the prepuce; the tumor may involve one or more of these anatomical compartments).⁴¹ If present, classify the foreskin as short, medium, long, and/or phimotic.² Cut the proximal margin of resection en face making sure to include the entire circumference of the urethra (Figure 1). If the urethra has been retracted, it is important to identify its resection margin and submit it entirely. The resection margin can be divided in three important areas that need to be analyzed: the skin of the shaft with underlying dartos and penile fascia; corpora cavernosa with albuginea; and urethra with periurethral cylinder that includes subepithelial connective tissue (lamina propria), corpus spongiosum, albuginea, and penile fascia (Figure 1). The urethra and periurethral cylinder can be placed in one cassette. The skin of the shaft with dartos and fascia can be included together with the corpora cavernosa. Because this is a large specimen, it may need to be included in several cassettes to include the entire resection margin. Fix the rest of the specimen overnight. Then, in the fixed state and if the tumor is large and involves most of the glans, cut longitudinally and centrally by using the meatus and the proximal urethra as reference points. Do not probe the urethra. Separate the specimen into halves, left and right (Figures 2 and 3). Then cut two to six serial sections of each half. If tumor is small and asymmetrically located in the dorsal or ventral area, the central portion of the tumor may be used as the axis of sectioning. If the tumor is large involving multiples sites (glans, sulcus and foreskin), it is important not to remove the foreskin leaving the entire specimen intact for sectioning.

In cases of small carcinomas exclusively located in the glans with no foreskin involvement, one may choose to remove the foreskin leaving a 3-mm redundant edge around the sulcus. Proceed cutting the foreskin as indicated for circumcision specimens. If the primary tumor is located in the glans, one should still submit the foreskin serially and in orderly fashion labeled from 1 to 12 clockwise. The rest of the penectomy specimen should be handled as described above.

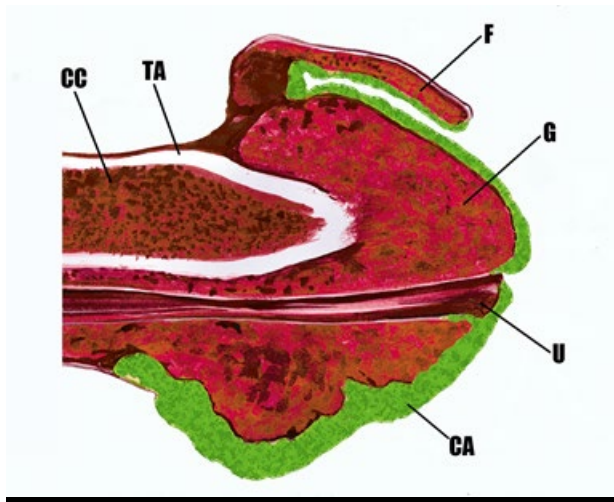


Figure 2. Partial penectomy specimen. After submitting the proximal resection margin, the specimen is cut in half longitudinally. Parallel serial sections will follow.

Abbreviations: CA, carcinoma; CC, corpus cavernosum; F, foreskin; G, glans; TA, tunica albuginea; U, urethra.

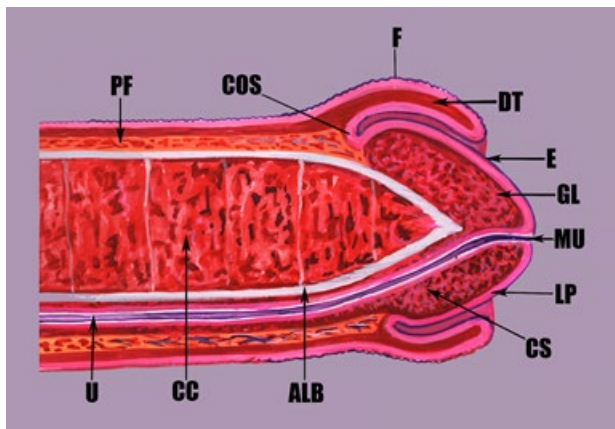


Figure 3. Longitudinal and central section showing the ventral urethra (U) and the penile main anatomic compartments: glans (GL), coronal sulcus (COS), and foreskin (F). The Buck's (penile) fascia (PF) encases the shaft and inserts into the coronal sulcus.

Abbreviations: ALB, albuginea; CC, corpus cavernosum; CS, corpus spongiosum; DT, dartos; E, epithelium; LP, lamina propria; MU, urethral meatus.

M. Pathology Report for Penile Squamous Cell Carcinoma

The report should contain the following information: primary tumor: tumor site or sites, size in centimeters, histologic subtype, histologic grade, anatomical level of invasion, tumor thickness in millimeters, and vascular and perineural invasion. In penectomy specimens, the margins of resection to be reported are urethral/periurethral, corporal, and skin of the shaft.¹ In circumcision specimens, margins include coronal sulcus mucosal margin and cutaneous margin. Common associated lesions to be reported are penile intraepithelial neoplasia (differentiated or undifferentiated), lichen sclerosus, and other "inflammatory dermatologic" conditions.

If the specimen is accompanied by inguinal nodes, the number and size of nodes should be described. All nodes should be included for microscopic examination. The number of positive nodes and total number of

nodes examined should be reported as well as the presence of extracapsular extension and the number and site (eg, inguinal versus pelvic) of metastatic nodes. The distinction between superficial and deep inguinal lymph nodes has been eliminated in the seventh edition TNM classification.²

References

1. Velazquez EF, Soskin A, Bock A, Codas R, Barreto JE, Cubilla AL. Positive resection margins in partial penectomies: sites of involvement and proposal of local routes of spread of penile squamous cell carcinoma. *Am J Surg Pathol*. 2004;28(3):384-389.
2. Amin MB, Edge SB, Greene FL, et al, eds. *AJCC Cancer Staging Manual*. 8th ed. New York, NY: Springer; 2017.